

Defining Relapses Attributed to Equine Protozoal Myeloencephalitis

Siobhan P. Ellison DVM PhD pathogenes inc.

PO Box 970 Fairfield, FL 32634

(352) 591-3221, f (352) 591-4318, sellison@pathogenes.com

KEY WORDS: EPM, *Sarcocystis neurona*, *Sarcocystis fayeri*, equine protozoal myeloencephalitis

ABSTRACT

Disease caused by *Sarcocystis* spp are associated with a variety of clinical signs including abortion, hemorrhages, hair loss, muscular disease, and neurological dysfunction. In horses, clinical disease is associated with *Sarcocystis fayeri* and *S neurona*. The genesis of and clinical progression of disease caused by these protozoans in horses is not well defined but acute, chronic, and relapsing disease is recognized in horses undergoing treatment and recovery from sarcocystosis. In this study, we investigated the seroprevalence of species specific antibodies to *S fayeri* and *S neurona* in horses to determine their association with specific aspects of disease progression. We identified three disease presentations associated with chronic sarcocystosis that have been clinically attributed to equine protozoal myeloencephalitis (EPM) caused by *S. neurona*.

Most relapsing remitting disease in this group of horses was due to *S fayeri* or autoimmune polyneuritis, not *S neurona*. We offer serological evidence that repeat environmental exposure to *S neurona*, rather than persistent but unapparent infections, causes disease; *S fayeri* toxin can be associated with persistent subclinical disease in clinically normal horses; and dysfunctional

inflammatory immune responses stimulated by these organisms can result in the development of clinical signs without the presence of parasite stages in tissue.

INTRODUCTION

Equine protozoal myeloencephalitis (EPM) is a serious disease syndrome in horses from the Americas. *Sarcocystis neurona* is most often associated with EPM and not usually present in muscle, while *S fayeri* produces muscular *sarcocystis* (EMS), which elicits inflammation and associated clinical signs. Diagnosis of EPM and EMS is difficult because no clinical signs are unique and can be caused by other disease producing agents.

Additionally, the immune response to *S fayeri* and *S neurona* induces inflammation that can cause clinical signs in horses and innate immune responses stimulated by *Sarcocystis* are not parasite species specific, thus the presentation of EPM and EMS can be indistinguishable. The causes of chronic parasite associated inflammation are not well defined, but are obviously important in some conditions. For example, demyelination due to autoimmune antibody is associated with polyneuritis in horses was first demonstrated by Kadlubowski and Ingram (1981). Fordyce et al developed an ELISA for the differential diagnosis of cauda equina neuritis and other neuropathies (1983), this assay was modified by Ellison et al (2015) and used to detect circulating antibodies in horses with suspected EPM. Repeat

exposure to *Sarcocystis* sporocysts from the environment may be important in stimulating a chronic inflammatory response. It is also possible that persistent infection with sarcocysts in muscle can induce chronic inflammation.

In an updated EPM consensus statement Reed et al (2016) reported that many clinically normal horses have serum antibodies against *Sarcocystis* merozoites, indicating that infection and subclinical disease is prevalent. Debilitating, presumably acute infections are seen in a small number of horses exposed to *S. neurona*. It is confounding to some veterinarians that protozoal exposure doesn't always result in EPM. *Sarcocystis fayeri* is present in horses world-wide. Aleman et al associated sarcocyst burden with equine neuromuscular disease (2014) and Ellison and Li (2016) reported circulating *S. fayeri* antitoxin in horses with neuromuscular disease.

Interestingly, there was a statistically significant correlation between *S. fayeri* antitoxin and acute phase inflammatory proteins in the study population. However, chronic inflammation was present in some horses during or after *S. neurona* or *S. fayeri* infections. After discontinuation of antiprotozoal treatment, EPM-horses often experience a recrudescence of signs, therefore this syndrome is appropriately termed post-treatment EPM (disease) syndrome (PTEDS).

Relapses can occur months to years after apparently successful initial treatment. The consensus opinion reported by Reed et al (2016) indicate that cycles of clinical improvement followed by a relapse can be due to re-exposure to *S. neurona* sporocysts or relapse may be due to persistent latent but unapparent infections. Ellison et al (2016) suggest that toxins released from *S. fayeri* sarcocysts may cause relapsing clinical signs that are attributed to *S. neurona*-EPM. Antibodies against *S. fayeri* are found in the CNS of some clinically ill horses. However, this finding is not clear (Ellison, data not shown). A consistent finding in equine clinical sarcocystosis is inflammation, Dubey et

al. (2016).

Horses with a history of PTEDS were enrolled into this study to differentiate conditions associated with EPM syndromes. Enrolled horses were evaluated quarterly for signs of neuromuscular dysfunction. Serum was assayed for antibodies against *S. neurona* surface antigens (SAG's 1, 5, 6), myelin protein, a neuritogenic peptide of equine myelin protein, *S. fayeri* toxin, and C-reactive protein concentration by enzyme linked immunosorbent assays.

MATERIALS AND METHODS

Sixty-nine adult horses of both sexes were identified by participating veterinarians based on recruitment using the following criteria. Each enrolled horse had at least one relapse of clinical signs of EPM after successful treatment using a licensed antiprotozoal agent (n=41), a licensed antiprotozoal agent and decoquinat/levamisole HCl (n=13), decoquinat/levamisole HCl (n=7), and had a normal neurological assessment by a veterinarian with a gait assessment (GAS) of 0 (n=47). A horse with a non-neurological lameness was scored with a GAS 1 (n=14). The gait assessment score (GAS) was used because it is accepted as clinically significant by the US Food and Drug

Administration for evaluating the effectiveness of EPM treatments for licensing were described in the Freedom of Information Summary for Marquis, Protazil, and ReBalance. A GAS of 0 is assigned when the gait is normal, a GAS of 1 is described as a neurologic deficit that may be detectable at normal gaits; signs are exacerbated with manipulative procedures (such as backing, turning in tight circles, walking with head elevated). A GAS of 2 is described as a neurological deficit obvious at normal gaits or posture; signs are exacerbated with manipulative procedures.

Serum was tested for selected antigens by ELISA, and horses were grouped by seroreactivity to *S. neurona* surface antigens (SAG's 1, 5, 6), *S. fayeri* toxin, myelin protein, and a neuritogenic peptide of equine myelin protein as previously described by

Ellison (2003), Ellison and Li (2016), and Ellison et al (2015) respectively. Groups included: SN (antibody against SAG's 1, 5, or 6 detected at a titer > 4), SF (*S fayeri* cyst antitoxin present at a titer > 4; with or without SN antibodies), and MPP (antimyelin or anti-neuritogenic peptide antibodies at a titer > 4; with or without SN or SF antibodies). Serum C-reactive protein (CRP) concentration was quantitated by ELISA (Genway, CA). A CRP serum concentration greater than 16 µg/ml was considered elevated, the range was 0-99 µg/ml. Horses were treated with 0.5 mg/kg oral decoquinatate in a feed pellet daily for 3-month intervals, horses that did not show signs of EPM continued in the study if the owners were compliant. Decoquinatate is believed to inhibit the early infective stages of parasitic protozoa.

At 3, 6, and 9 months of daily treatment, gait was evaluated clinically by the attending veterinarian, serum samples were obtained at the time of examination. Evaluable data required the veterinarians signature, a gait score, and a serum sample submitted for testing. A horse was scored as success if the GAS was 0 and a fail if the GAS was > 0. Statistical analysis was done at 3 months to compare success or failure of treatment between groups (groups were defined based on study entrance seroreactivity). Data was evaluated at 6 and 9 months however, there were insufficient cases for statistical evaluation. Horses in the MPP group that failed were removed from the study and treated based on the Kuzma-Mroczkowska et al (2016) protocol that is used in children with frequently relapsing and steroid-dependent nephrotic syndrome.

RESULTS

Three-Month Analysis

Sixty-one horses were enrolled in the study after 3 months of daily decoquinatate treatment. There were 5, 30, and 26 animals in the SN, SF, and MPP groups, respectively (Figure 1). Disease did not reoccur in 80% of the animals. The percent success was 100% of the horses in the SN group, 90% of the horses in the SF group, and 65% of the

horses in the MPP group, (Table 2). Fishers exact test was used to compare the success between sarcocystosis and polyneuritis, treatment was more effective in treating sarcocystosis as compared to polyneuritis ($p < .05$). Most clinically normal horses had a serum CRP concentration above 16 µg/ml after 3 months in the study. All horses in the SN group had an elevated CRP, 23% of the SF group had elevated values, and 76% of the MPP group had an elevated CRP. Seventy-eight percent of the MPP group and 100% of the SF group that showed clinical signs in the three-month period had elevated CRP levels.

Six-Month Analysis

Thirty-three horses completed 6 months in the study. There were 4, 15, and 14 animals in the SN, SF, and MPP group, respectively (Figure 1). Clinical disease was not seen in 97% of the horses evaluated at 6 months. All the horses in the SN and SF groups and 93% of the MPP group did not show clinical disease.

There were less seropositive animals when assayed for *S neurona* SAG's, *S fayeri* toxin, and autoimmune antibodies at 6 months when compared to 3 months (Figure 3). The horses that remained seropositive for *S neurona* SAG 1, 5, 6 showed increasing titers (data not shown) while horses that were positive for *S fayeri* toxins did not show an increase in titer (data not shown).

At 6 months, elevated CRP was noted in 75% of the clinically normal SN group, 33% of the clinically normal SF group, and 62% of the clinically normal MPP group. All the MPP horses that showed clinical signs at 6 months had an elevated serum CRP concentration.

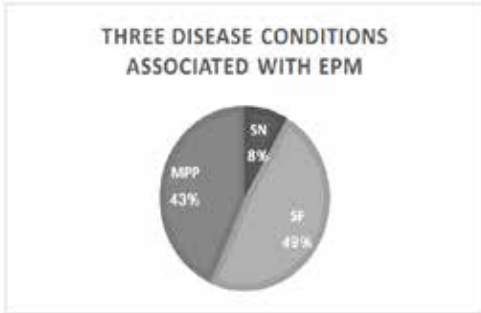
Nine-Month Analysis

Twelve horses completed 9 months of daily treatment. There were 2, 4, and 6 animals in the SN, SF, and MPP group, respectively. All horses in these groups were clinically normal at nine months.

Horses in the MPP Group Removed from the Study

Horses that were MPP positive and showed

Figure 1. Distribution of three disease conditions associated with PTEDS at the onset of the study. Most horses with PTEDS had *S.fayeri* toxicosis (SF group) or antibodies against myelin protein (MPP group), clinically described as autoimmune polyneuritis. The SN group was the least represented in this population of chronic/relapsing horses.



clinical signs of EPM were removed from the study.

DISCUSSION

Post-treatment EPM disease syndrome is common and often attributed to EPM-treatment failure. This study selected a popula-

tion of horses that had a high probability of exhibiting PTEDS to determine the etiology of remitting/relapsing clinical neuromuscular dysfunction in horses that received EPM treatment. There were three disease conditions associated with PTEDS (Figure 1). The smallest number of horses with a history of relapsing disease had an SN designation, and these horses were seropositive for *S. neurona* SAG 1, 5, or 6 antigens (Figure 2). The results suggest most of the presently assumed “treatment failures” are perhaps horses treated for the wrong disease because 92% of these historically “relapsing” horses did not have proof of *S. neurona* that was uncomplicated with another disease state. Most horses with PTEDS had circulating *S.fayeri* antitoxin or antimyelin protein antibodies (Figure 1). Treatment with decoquinatate was significantly more effective in treating sarcocystosis as compared to polyneuritis ($p < .05$) when success was determined by an absence of clinical signs of EPM in these horses (Figure 2).

In this study, the most successful outcome was seen in horses that were in the *S*

Figure 2. The veterinary examinations for study animals are shown at 3, 6, and 9 months in the study. The absence of clinical signs associated with relapse, scored as a “success”, GAS = 0. A score of “fail” indicated any clinical signs of relapse or a gait assessment > 0. Horses were put into the SN group if *S. neurona* antibodies were present, *S.fayeri* group if *S.fayeri* antitoxin, with or without *S. neurona* antibodies, were present, and if autoantibodies against equine myelin protein was present the animal was grouped as MPP. Treatment was more effective in treating sarcocystosis (SN and SF) as compared to polyneuritis (Fishers exact test, $p < .05$).

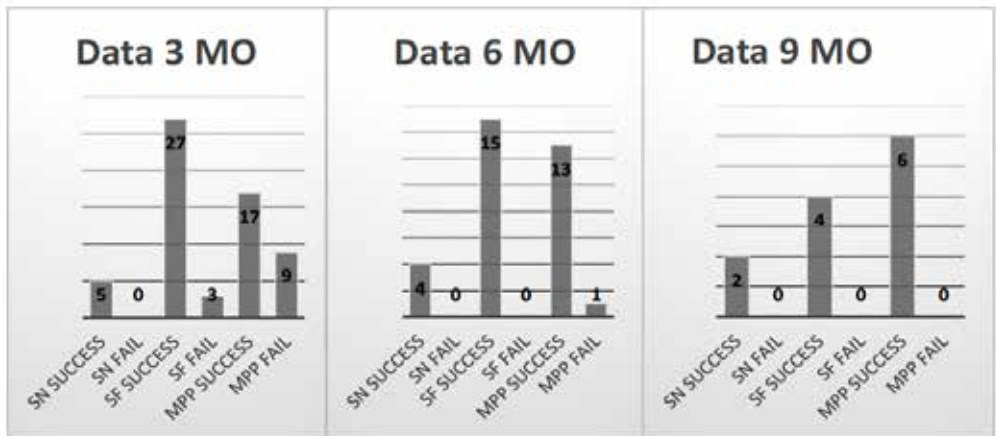


Table 1. Chart showing the percent of the animals, by group, with elevated CRP concentrations (>16 µg/ml) at 3 and 6 months in horses scored as success or fail, perhaps indicating the presence of subclinical inflammation. The number of animals seropositive for *S. neurona* (SN), *S. fayeri* (SF), or myelin protein (MPP) at 3 and 6 months are shown.

CRP >16 µg/ml	SN success	SN fail	SF success	SF fail	MPP success	MPP fail
3 months	100%	0%	23%	100%	76%	78%
6 months	75%	0%	19%	0%	62%	100%
Seropositive	SN		SF		MPP	
3 months	37	na	33	na	16	na
6 months	14	na	15	na	8	na

neurona group. The horses with antimyelin protein antibodies had the highest number of treatment failures and were more likely to demonstrate exacerbated signs of neuromuscular disease. These results indicate a more accurate diagnosis is necessary to effectively select horses for EPM treatment using an antiprotozoal agent.

The number of seropositive animals (SN, SF, and MPP) decreased over time. In this study, at enrollment some *S. fayeri* animals were seropositive for *S. neurona*, and horses with autoimmune polyneuritis were seropositive for *S. neurona* and/or *S. fayeri*, it would be expected that without re-exposure to *Sarcocystis* animals would seroconvert to negative. Pusterla et al (2013) reported in one study that the length of time for seropositive *S. neurona* horses to convert to seronegative, irrespective of treatment or no treatment, was 5-6 months.

It was interesting that the SN group animals in the current study had increasing SAG 1, 5, or 6 antibody titers during the study (data not shown), but showed no signs of disease. Increasing SAG antibodies may indicate that there was continued exposure to *S. neurona* in the environment. Repeated environmental exposure to *S. neurona* may stimulate antibody against SAG 1, 5, or 6 antigens resulting in a rising titer. These results contrast with other prophylactic studies in which *S. neurona* antibodies declined in horses treated with triazine agents. Studies designed to prevent EPM, ponazuril-treated

oocyst-challenged horses, (Furr et al, 2006) and a field study using diclazuril continually fed to high risk foals (Pusterla et al, 2015), indicated that *S. neurona* antibodies were delayed or declined. Furr et al (2006) showed that prophylactic administration of ponazuril (triazines) did not prevent EPM in sporocyst challenge horses because clinical disease accompanied the decline in *S. neurona* antibodies.

The biology of the parasite including stage-related antigen expression may explain the current study results. Sporozoites are short lived. Sporozoites become a 1st-generation schizont that produces 1st generation merozoites, which may destroy host cells. The 2nd generation merozoites must become sarcocysts. Sporozoites minimally express SAG 2, 3, 4, and 5. These are immunodominant surface antigen expressed by merozoites. Collectively, it was shown by Howe et al (2008), Miller et al (2004), and Wendte et al (2010) that *Sarcocystis neurona* SAG 1, 5, and 6 are mutually exclusive genes found in strains of *S. neurona*. Therefore, it is anticipated that SAG 1 and SAG 6 would also show minimal expression in sporozoites and expression followed by down regulation in some merozoite stages as shown for SAG 5 by Gautam et al (2011).

Differences in antigen selection to detect *S. neurona* in the triazine-prevention studies and those used in this study, SAG 1, 5, and 6, may reconcile the differences in antibody detection. Although sporozoites may express

little SAG 1, 5, and 6, the first generation merozoites could release antigens detected by our assay. This study used the presence of anti-toxin as a marker for *S fayeri* to clearly separate the immune response to the two species that infect horses. Although bradyzoites of *S fayeri* may express cross-reactive surface antigens to *S neurona* the sarcocyst toxin is unique to the cyst stage.

Triazine drugs didn't affect the intestinal stages of sporozoites or SAG 1, 5, 6 antigen antibodies would have increased in the prophylaxis studies. It is possible that triazine drugs inhibit development of 1st-generation schizonts -not sporozoites entering cells, and after treatment, inhibited stages began dividing again, and these merozoites initiate proinflammatory responses causing clinical disease, but no measurable antibody response.

Others reported that triazine agents kill some merozoite stages of the protozoa, while other stages are inhibited and retain the ability to begin development again once the drug is removed. Dirikolu et al (2013) speculated that in horses, intact immune responses can likely remove most of the inhibited stages in cases of successful treatment. In unsuccessful cases, relapse occurs because some infectious stages are not completely removed. In this scenario, antibodies against some antigens are expected to decline while clinical signs reoccur due to an exacerbation of selected organisms. In the current study, animals didn't show clinical signs of disease, therefore progressive infection was not indicated.

Lindsey et al (2013) showed that decoquinat kills merozoites (in vitro), possibly 1st generation merozoites in the gut are prevented from disseminating to organs and stimulates gut-mediated immunity that may not induce pathologic pro-inflammatory responses. In this study, antibodies may differentiate new infections from previously treated infections because 1st generation merozoites (derived from sporozoites) would display different antibody profiles than merozoites that were exacerbations

from silent infections. It is anticipated that chronic dysfunctional inflammatory reactions that target neuromuscular tissues would not be affected by anti-protozoal agents unless there was an active infection.

Levels of *S fayeri* antitoxin decreased at 6 months in this study, indicating sarcocysts were no longer stimulating the production of antitoxin, or new toxin-secreting sarcocysts were not formed, in these clinically normal animals. *Sarcocystis fayeri* infection was evaluated by measuring antitoxin, rather than antibodies against *S fayeri* merozoite surface antigens. Although it was not done in this study, it is expected that an assay for *S fayeri*-specific surface antibodies found on merozoites would show an increasing titer if *S. fayeri* was present in the environment, as seen in the *S neurona* exposed horses in this study.

A decrease in *S fayeri* antitoxin may be due to degradation of muscle sarcocysts or inhibition of new sarcocyst formation. In other studies, conducted by Smith et al (1989), inflammation in striated muscles was weakly related to the schizont burden (not sarcocyst burden) and strongly related to myocyte degeneration, suggesting that inflammatory cell response was principally due to myocytic necrosis and not the parasites. These challenge experiments showed that schizonts of *S falcatula* were not toxigenic. Encephalitis was present in all challenged birds. Despite the absence of clinical disease, subclinical disease was present. The CRP results in the current study support the presence of subclinical and clinical inflammation associated with *S fayeri* in horses. However, an elevated CRP was most often associated with clinical disease.

Horses with antimyelin protein antibodies that relapsed were removed from the study and treated for autoimmune polyneuritis. The MPP group showed the largest number of animals with recurrent signs and, as expected, this disease did not respond to the antiprotozoal therapy. Chronic inflammation, resulting in autoimmune neurological dysfunction, is suggested in humans diag-

nosed with multiple sclerosis (MS). Lehmann-Horn et al (2013) suggest plasma cells, which secrete autoreactive antibodies seen in MS, contribute to demyelination within the inflamed central nervous system. Ellison et al (2015) showed autoimmune polyneuritis, perhaps an MS-like equine neuromuscular disease, and PTEDS, are associated with antimyelin protein antibodies. Murrell et al (1986) speculated that the pathogenesis of immune-mediated MS is associated with neurotoxins released from *Sarcocystis* sarcocysts. It is possible that a similar disease mechanism is present in humans and horses. The mechanism of *Sarcocystis*-associated autoimmune polyneuritis in horses is unknown, but the pathology may be cytokine mediated because CRP is stimulated by IL6 and Ellison et al (2015a, 2015b) showed increased CRP levels in horses with autoimmune polyneuritis. Understanding the pathogenesis of EPM would require identification of the disease processes that are mediated by inflammation.

The CRP serum concentrations were elevated in all the SN group horses at 3 months and values declined in a small number of horses by 6 months (Table 3). The CRP concentrations tended to decrease in the asymptomatic *S.fayeri* group at 6 months, perhaps indicating the animals were not being re-exposed. The absence of *S.fayeri* antitoxin and a declining CRP in study horses may indicate removal of sarcocysts. Inflammation, measured by CRP concentration, was less prevalent in the clinically normal *S.fayeri* horses when compared to the *S.neurona* horses suggesting that *S.neurona* infections in an aberrant host is more inflammatory than *S.fayeri* in its normal intermediate host, or there are repeated acute *S.neurona* infections. Proinflammatory responses, possibly suggesting the contribution of inflammation to clinical signs of EPM, are not uncommon in the pathogenesis of sarcocystosis in true intermediate hosts as shown by Smith et al (1989).

In this study, the CRP concentration decreased slightly in the asymptomatic MPP

group. However, sub-clinical autoimmune inflammatory disease was still present in most of these horses.

This study indicates that there are three etiologies of relapsing signs in horses with PTEDS. Each syndrome may require a different treatment and have a different prognosis. All etiologies were associated with inflammation measured by an elevated CRP concentration. This study indicates that horses with a clinical history of relapsing/remitting *S.neurona* are not a recrudescence of existing parasites, but rather re-exposure and infection because these chronic EPM horses demonstrated an increasing titer to *S.neurona* SAG's but no clinical disease.

Sarcocysts are initially derived from intestinal infections. Sporozoites of most *Sarcocystis* penetrate the epithelial cell surface of intestine of intermediate host and migrate to endothelial cells of capillaries and then divide by schizogony, or they migrate to hepatocytes then start schizogony. Two generations of schizogony occur and merozoites eventually penetrate muscle. Merozoites divide by endodyogeny in muscle cells and are called metrocytes. In sarcocysts metrocytes produce other metrocytes or bradyzoites by endodyogeny. Mature sarcocysts contain only bradyzoites. The cause of sarcocyst degeneration is not known, but the released toxins may be antigenic.

Polyneuritis and encephalomyelitis can be a consequence of inflammatory cytokines that can enter the CNS in the absence of in situ organisms as seen by Melo and Machado (2009) in other protozoal disease. Anti-protozoal treatments do not address the component of inflammation associated with sarcocystosis as shown in this and other studies conducted by Furr et al (2006) and Ellison et al (2015a, 2015b).

The presence of circulating CRP in horses with clinical and sub-clinical autoimmune polyneuritis, the MPP group in this study, may indicate a pathologic state of chronic inflammation. It is possible that treatment for the autoimmune component of disease could be monitored using the

CRP concentration. Horses identified as MPP that failed were removed from this study (n=12). Ten removed horses were monitored and received treatment (modified Kuzma-Mroczkowska protocol) for underlying autoimmune disease (data not shown). Clinical signs resolved within days of initiation of therapy, however, at 2-4 weeks the serum CRP concentrations remained elevated and the horses tended to relapse days to months after discontinuation of 2 weeks of therapy. Because resolution of clinical signs preceded a reduction in CRP concentration in these horses with autoimmune polyneuritis, subclinical disease may require extended therapy to resolve immune-mediated inflammation and prevent relapses. More work is needed to determine the relationship between resolution of clinical signs and disease as it relates to CRP concentration in MPP horses.

ACKNOWLEDGEMENTS

This study was funded by Pathogenes Inc. The author thanks Dr. Tom Kennedy and Dr. David Lindsay for reviewing the manuscript.

REFERENCES

- Aleman M, Shapiro K, Siso S, Williams DC, Rejmanek D, Aguilar B, Conrad PA., 2015. "Sarcocystis fayeri in skeletal muscle of horses with neuromuscular disease." *Neuromuscul Disord*, 41-5.
- Dirikolu L, Foreman JH, Tobin T., 2013. "Current therapeutic approaches to equine protozoal myeloencephalitis." *JAVMA*, 482-491.
- Dubey JP, Calero-Bernal R, Rosenthal BM, Speer CA, Fayer R., 2016. *Sarcocystosis of Animals and Humans*. CRC Press Taylor and Francis, p 159.
- Ellison SP, Kennedy T, et al. "Development of an ELISA to detect antibodies to rSAG1 in the horse." 2003. *J App Res Vet Med.*, 318-327.
- Ellison S, Kennedy T, Li A, Schweiss L., 2015a. "Serum antibodies against a reactive site of equine myelin protein 2 linked to polyneuritis equi found in horses diagnosed with EPM." *Int J Appl Res Vet Med*, 164-170.
- Ellison Siobhan, Witosky Sharon, 2009. "Evidence that antibodies against recombinant SnSAG1 of *Sarcocystis neurona* merozoites are involved in infection and immunity in equine protozoal myeloencephalitis." *The Canadian Journal of Veterinary Research*, 176-183.
- Ellison SP, Kennedy TK, Li A., 2015b. "Neuritogenic Peptides derived from Equine Myelin P2 basic protein detect circulating antibodies in ataxic horses." *Intern J Appl Res Vet Med*, 175-181.
- Ellison, Siobhan and Austin Li., 2016. "Sarcocystis fayeri anti-toxin in serum from horses with neuromuscular disease." *Intrn J Appl Res Vet Med*, 152-158.
- Fordyce S, Edington N, Bridges GC, Wriht JA, Edwards GB., 1987. "Use of an ELISA in the differential diagnosis of cauda equina neuritis and other equine neuropathies." *Equine Veterinary Journal*, 19, 55-59.
- Furr M, McKenzie H, Saville WJ, Dubey JP, Reed SM Davis W., 2006. "Prophylactic administration of ponazuril reduces signs and delays seroconversion in horses challenged with *Sarcocystis neurona*." *J Parasitol.*, 92(3), 637-43.
- Gautam A, Dubey JP, Saville WJ, Howe DK., 2011. "The SnSAG merozoite surface antigens of *Sarcocystis neurona* are expressed differentially during the bradyzoite and sporozoite life cycle stages." *Veterinary Parasitology*, 183, 37-42.
- Howe DK, Rashekhar GY, Marsh AE, Patil BA, Sville WJ, Lindsay DS, Dubey JP, Granstrom DE., 2008. "Strains of *sarcocystis neurona* exhibit differences in their major surface antigen including the absence of the major surface antigen SnSAG1." *Int J Para.*, 623-631.
- Kadlubowski M, Ingram PL., 1981. "Circulating antibodies to the neurotogenic myelin protein 2, in neuritis of the cauda equina of the horse." *Nature*, 293, 299-300.
- Kuzma-Mroczkowska K, Skrzypczyk P, Panczyk-Tomaszewska M., 2016. "Levamisole therapy in children with frequently relapsing and steroid-dependent nephrotic syndrome: a single-center experience." *Central European Journal of Immunology*, 243-247.
- Lehmann-Horn K, Kronsbein C, Weber MS., 2013. "Targeting B cells in treatment of Multiple Sclerosis: recent advances and remaining challenges." *Therapeutic Advances in Neurological Disorders*, 161-173.
- Lindsay DS, Nazir MM, Maqbool A, Ellison SP, Strobel JS., 2013. "Efficacy of decoquinate against *Sarcocystis neurona* in cell cultures." *Vet Parasitol.*, 21-23.
- Mackay, R J., 1997. "Serum antibodies to *Sarcocystis neurona*-half the horses in the United States have them!" *J Am Vet Med Assoc.*, 482-3.
- Melo G, Machado G., 2009. "Choroid plexus involvement in dogs with spontaneous visceral leishmaniasis: a histopathological investigation." *Brazilian Journal of Veterinary Pathology*, 69-74.
- Miller MA, Barr BC, Nordhausen R, James ER, Magargal SL, Murray M, Conrad PA, Toy-chouka S, Jessup DA, Grigg ME., 2004. "Ultrastructural and molecular confirmation of the development of *Sarcocystis neurona* tissue cysts in the central nervous system of southern sea otters (Enhydra lutris nereis)." *Intern J Parasitol.*, 39, 275-284.
- Murrell TG, O'Donoghue PJ, Ellis T., 1986. "A review of the sheep-multiple sclerosis connection." *Med Hypotheses.*, 27-39.
- Pusterla N, Packham A, Mackie S, Kass P, Hunyadi L, Conrad P., 2015. "Daily feeding of diclazuril top dress pellets in foals reduces seroconversion

- to *Sarcocystis neurona*." *The Veterinary Journal*, 206, 236-238.
22. Pusterla N, Packham A, Wilson WD, White A, Bellamy P, Renier AC, Conrad PA., 2013. "Evaluation of the kinetics of antibodies against *Sarcocystis neurona* in serum from seropositive healthy horses without neurological deficits treated with ponazuril paste." *Veterinary Record*, 173 (10), 249.
 23. Reed SM, Furr M, Howe DK, Johnson AL, MacKay RJ, Morrow JK, Pusterla N, Witonsky S., 2016. "Equine Protozoal Myeloencephalitis: An updated consensus statement with a focus on parasites biology, diagnosis, treatment, and prevention." *J Vet Int Med.*, 1-12.
 24. Smith J, Neill J, Box E., 1989. "Pathogenesis of *Sarcocystis falcatula* (Apicomplexa: Sarcocystidae) in the budgerigar (*Melopsittacus undulatus*) iii. Pathologic and quantitative parasitologic analysis of extrapulmonary disease." *J Parasitol.* 270-287.
 25. Wendte JM, Miller MA, Nandra AK, Peat SM, Crosbie PR, Conrad PA, Grigg ME., 2010. "Limited genetic diversity among *Sarcocystis neurona* strains infecting southern sea otters precludes distinction between marine and terrestrial isolates." *Vet Parasitol.*, 1-8.